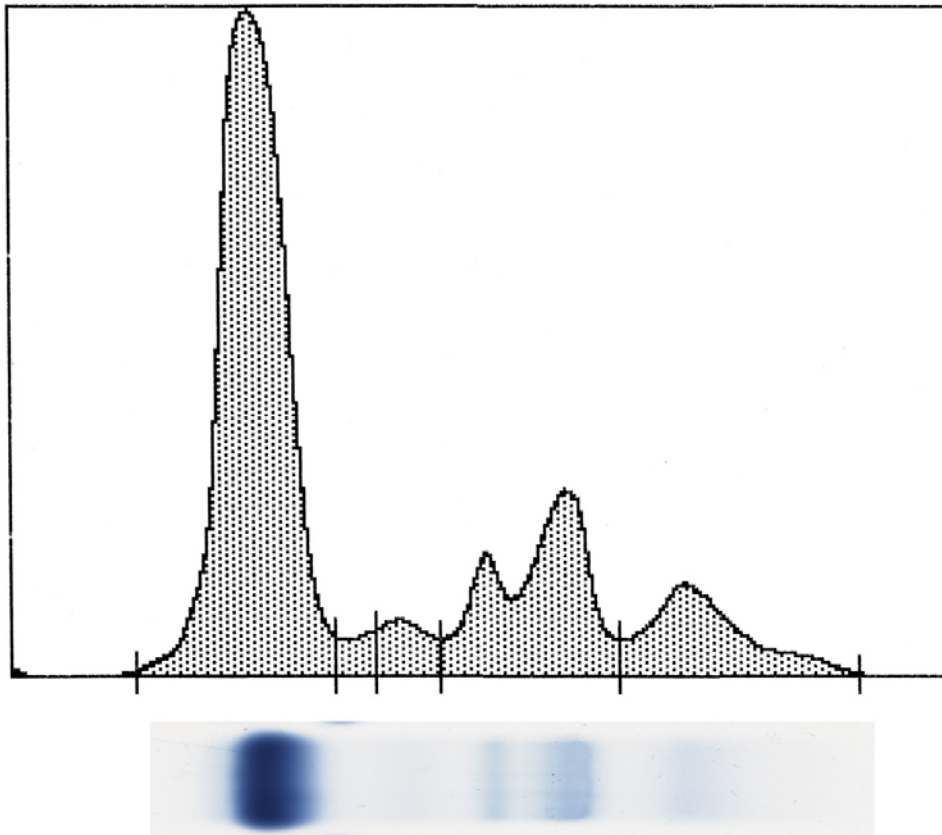


Clinical Case 1: EPH and Sarcocystosis

Normal EPH

This is a normal EPH pattern from an African Grey Parrot. African Grey Parrots often have low or no visible prealbumin fraction. Albumin, in a normal animal, is the predominant fraction as shown here. Albumin can decrease with acute inflammation. Alpha 1 globulins are not commonly found in significant levels in psittacines (but are a major fraction in other avian species). A small alpha 2 fraction is demonstrated below. This fraction can increase non specifically with acute inflammation. In African Greys as well as a few other parrot species, beta globulins are present as a double peak. The gamma globulins shown below conform to the normal polyclonal resting pattern.

In EPH interpretation, the clinical pathologist examines both this densitometer tracing as well as the gel itself (shown underneath the tracing below). The two give a combined impression with the quantitated fractions to lead the pathologist to give the submitting veterinarian the most accurate interpretation possible.

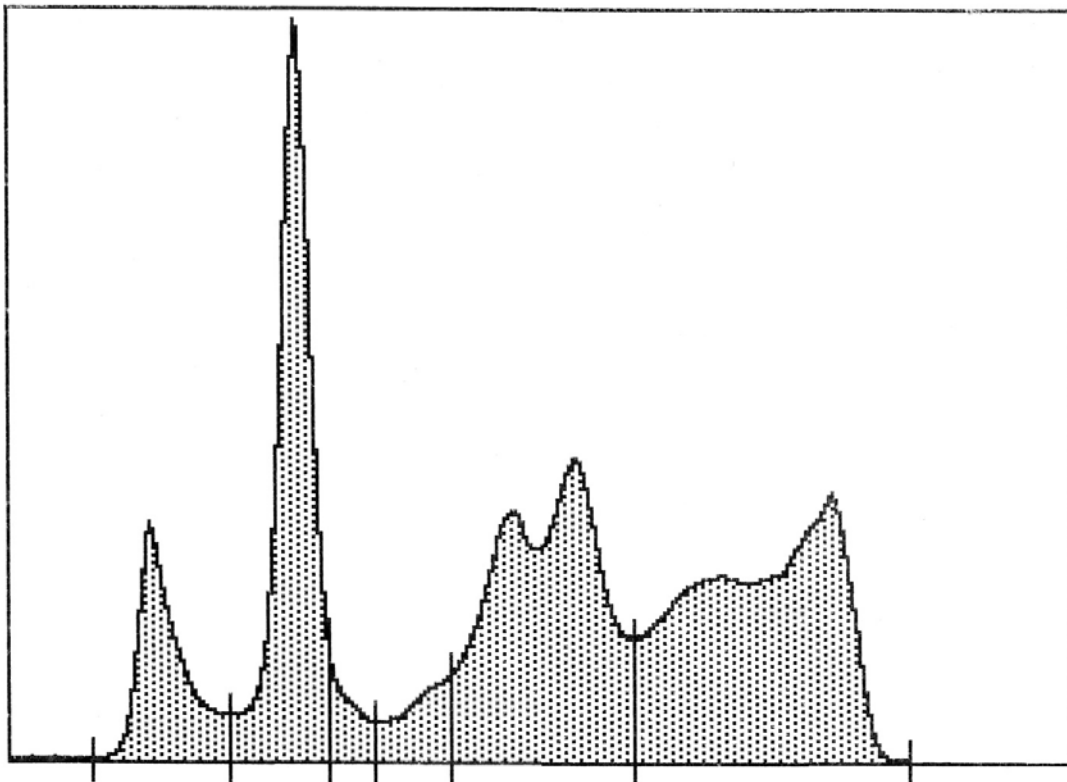


From left to right: albumin, alpha 1, alpha 2, beta, and gamma globulins. The prealbumin fraction is absent in this bird. The A/G ratio is 1.59.

Bird with confirmed Sarcocystosis

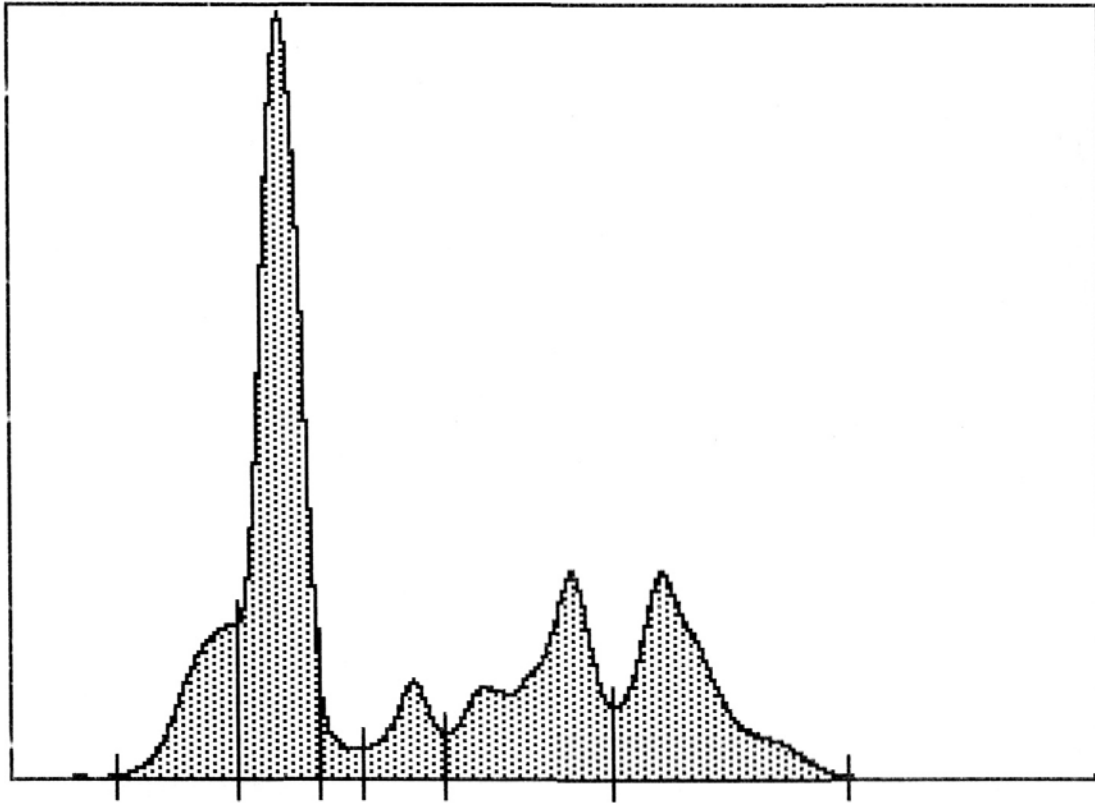
The laboratory is conducting a research project in association with many referring veterinarians in regards to the application of an IFA serology test for antibody and EPH in the antemortem diagnosis of birds with a chronic form of sarcocystosis. This study is in press in the *Journal of Avian Medicine and Surgery*.

An example of one of the cases is shown below. Birds with the chronic form of disease often present with neurological signs, lameness, muscle weakness, and lethargy. A typical EPH profile includes elevated beta and gamma globulins. By IFA serology, antibody titers are detected. With positive response to treatment, although the positive serostatus remains, the EPH abnormalities will resolve. EPH thus is an important prognostic indicator in this type of disease.



EPH submission prior to diagnosis

From left to right : prealbumin, albumin, alpha 1, alpha 2, beta, and gamma globulins. A/G ratio = 0.49; IFA titer to Sarcocystis: 1:25



EPH submission one month post initiation of treatment

From left to right: prealbumin, albumin, alpha 1, alpha 2, beta, and gamma globulins, A/G ratio = 1.06